

Zirconia Crowns with Porcelain Veneers for Optimal Esthetics in Children Using CAD/CAM Technology: A Case Report

Pegah Bakhtiary , Parissa Aref  

Department of Pediatric Dentistry,
Faculty of Dentistry, Tehran Medical
Sciences, Islamic Azad University,
Tehran, Iran

Corresponding author:

Parissa Aref, Department of Pediatric
Dentistry, Faculty of Dentistry, Tehran
Medical Sciences, Islamic Azad
University, Tehran, Iran

parissa234@yahoo.com

Article History

Received: 20 November 2021

Accepted: 3 February 2022

Abstract

Background and Aim: Stainless steel crowns (SSCs) are the gold standard for restoration of severely damaged primary teeth. However, the unesthetic appearance of SSCs is responsible for their lower acceptance by clinicians and patients. Zirconia crowns are another option for reconstruction of severely damaged teeth, which also provide optimal esthetics.

Case Presentation: Our patient was a 5-year-old child with a carious primary mandibular first molar. A prefabricated zirconia crown was considered for the tooth because the parents disapproved the color of SSC. The computer-aided design/computer-aided manufacturing (CAD/CAM) technology was used to fabricate a zirconia crown with porcelain veneering since the size of prefabricated crowns did not match the size of the respective tooth.

Conclusion: At the 1-year follow-up, the crown fabricated with this technique showed optimal esthetics, function, and durability. Although these crowns have shortcomings such as the risk of porcelain chipping, and require greater tooth preparation than SSCs, they can serve as a suitable alternative for reconstruction of severely damaged primary teeth when esthetics is an important parameter to consider.

Key Words: Computer-Aided Design; Tooth, Deciduous; Dental Porcelain; Zirconium

Cite this article as: Bakhtiary P, Aref P. Zirconia Crowns with Porcelain Veneers for Optimal Esthetics in Children Using CAD/CAM Technology: A Case Report. *J Res Dent Maxillofac Sci.* 2022; 7(3):168-174.

Introduction

Unesthetic primary teeth in preschool children can negatively affect their social relations and psychological wellbeing. On the other hand, optimal esthetics of primary teeth can create a sense of satisfaction in children and their parents [1]. Stainless steel crowns (SSCs) are the gold standard for restoration of severely damaged primary teeth. However, the unesthetic appearance of SSCs is responsible for their lower acceptance by clinicians and patients. Due to increased demand for dental

esthetics, several crowns have been proposed for this purpose [2].

Zirconia crowns are a suggested option for reconstruction of severely damaged teeth, which also provide optimal esthetics [3]. The indications for use of zirconia crowns for primary teeth are the same as those for full-coverage crowns. These include large carious lesions that compromise the strength of the tooth, multiple or large proximal caries, crown build-up after pulp therapy, and hypoplastic teeth. Zirconia crowns are

clinically acceptable, and the parents are more satisfied with zirconia crowns than other full-coverage restorations. Zirconia crowns also show optimal biocompatibility, high strength, less wear against the opposing primary and permanent teeth, less potential for gingival irritation in primary teeth, and higher durability. Zirconia crowns cannot be crimped; thus, the tooth must be prepared to adapt to the crown [1]. High-strength zirconia copings veneered with feldspathic porcelain are commonly used to reconstruct permanent teeth in adults. High-strength zirconia copings are used to reinforce all-ceramic restorations and inhibit the formation of cracks that initiate from the internal surface of all-ceramic crowns [4]. The conventional glass-ceramics have optimal optical properties such as good color match with the adjacent teeth and high translucency. However, they have poor physical properties. Zirconia also has high stability and low translucency. Due to such poor optical properties, zirconia is used as a coping, and is veneered with tooth-colored ceramics for higher esthetics [5].

The computer-aided design/computer-aided manufacturing (CAD/CAM) technology has dramatically advanced since its introduction by Dr. Francois Duret and Dr. Werner Mormann. At present, this novel technology is available in dental clinics and laboratories. It enables the fabrication of full-ceramic crowns, inlays, onlays, and veneers in a shorter time using a software program. The materials used in the CAD/CAM systems include ceramics, resin ceramics, hybrid ceramics, and zirconia blocks [6]. The CAD/CAM technology used to fabricate restorations decreases human errors and provides superior esthetic results [7].

Herein, we report a pediatric patient for whom zirconia coping was fabricated for a primary mandibular first molar by the CAD/CAM technology, and veneered with porcelain by the layering technique in a

laboratory to obtain maximum esthetics and adaptation. Prefabricated zirconia crowns could not be used for this tooth due to its specific anatomy, small size, and short height. Thus, this novel treatment modality was used to achieve favorable retention and optimal adaptation, along with maximum esthetics.

Case Presentation

Figure 1 shows the pretreatment photograph and radiograph of the patient. The patient was a 5-year-old child with a carious primary first molar presenting to a private clinic in Tehran. The patient complained of pain in mandibular first molar (Figures 1a & b).

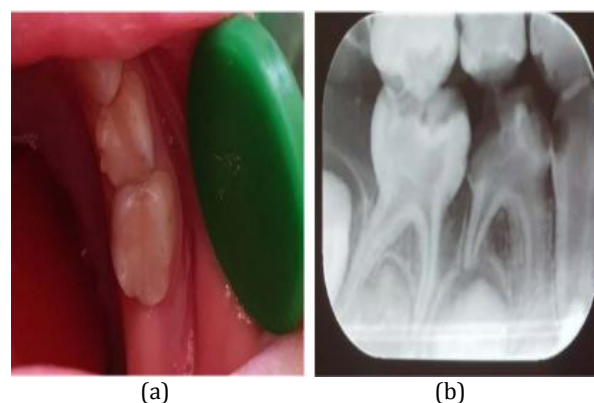


Fig. 1. (a) Intraoral photograph and (b) radiograph of the primary first molar before treatment

The patient's medical history was unremarkable. Figure 2 presents the photographs of tooth preparation procedure for zirconia crown. After clinical and radiographic examinations, and signing informed consent form by the parents, the respective tooth underwent pulpectomy (Figure 2a). SSC was suggested for reconstruction of the respective tooth. However, the parents disapproved the color of SSC and asked for a more esthetic restoration. Thus, a prefabricated zirconia crown was considered for the tooth. However, considering the tooth size, which did not match the size of any of the available prefabricated zirconia crowns, it was decided to fabricate a zirconia coping with

porcelain veneering. After the inferior alveolar nerve block with 2% lidocaine (Xylopen, Exir Tehran, Iran), pulpectomy was performed. Then, one layer of glass ionomer (Fuji-IX4, GC Co, Tokyo, Japan) was applied over zinc oxide eugenol (Master-dent, Dentonics, Inc., Monroe, NC, USA) to prevent the effect of eugenol on resin cement.

Preparation steps for the zirconia crown:

To create a suitable anatomy, the occlusal surface had to reduce by 1.5 to 2 mm. The margins received 1 mm deep chamfer preparation. The axial walls were tapered by 6-8°.

Step 1: Marginal design

The margins received 1 mm deep chamfer preparation, which allows more precise preparation of presintered zirconia. Using feather-edge finish lines instead of chamfer would be associated with a higher risk of chipping of the presintered zirconia in the process of preparation [8,9].

Step 2: Preparation of axial walls

The preparation should have a 6-8° taper starting from the margin to one-third of the occlusal surface. All angles, margins, and sharp edges should be rounded.

Step 3: Occlusal surface reduction

The central groove of the occlusal surface should be reduced by 1.5-2 mm. This space allows for creation of the correct anatomy of the occlusal surface. If the occlusal surface reduction is less than 1 mm, the crown morphology would be typically saucer-shaped. The clinician may need to reduce the zirconia surface to create an optimal anatomy instead of a natural appearance (Figure 2b) [8,9].

Impression making and laboratory steps:

After tooth preparation, a putty-wash impression was made from the mandibular arch using polyvinyl siloxane impression material (Spidex®, Coltene AG Altstätten, Switzerland) (Figure 2c). An alginate impression was also made from the maxillary arch, and bite registration wax was used to record the jaw relations. The impressions were

sent to a laboratory and poured with Vel-Mix dental stone (Interstone, New type IV, Slovenia). Each cast was separately scanned by a 3D scanner (MDS 500 Dental Scanner, Maestro 3D System, Pontedera, Italy) (Figure 2d). The zirconia core was designed as a coping since we wanted to apply porcelain veneering over it. The collected data were sent to a CAD system (Exocad, DentalCad 2.2 Valletta, Germany). The scanned image in the software included the mandible. Exocad can automatically estimate the correct axis and also has a tool to adjust the restoration design (adjusting the occlusal and interproximal contact points). A semi-sintered zirconia block (Zircostar High Strength Zirconia Blank, Kerox Dental, Hungary-EU) was used to fabricate the crown. The block was milled with a tungsten carbide bur in a milling machine (Pixodent Eco1; DentalCad 2.2, Exocad, Valletta, Germany). The crown was finished and polished in three steps. In the first step, a fine-grit diamond bur with a low-speed handpiece (MHL-L0-1, Mident, Hong Kong) was used. In the second step, rubber zirconia polishers were used. Finally, a polishing paste was applied by a low-speed buff (Figure 2e).

Zirconia coping was cleaned with alcohol in an ultrasonic bath (SUN-U520, Medical Expo, USA). Next, feldspathic porcelain powder was mixed with liquid (Vita Modeling Liquid; Vita Zahnfabrik, Bad Säckingen, Germany) according to the manufacturer's instructions, and applied on the coping surface by a microbrush. In order to compensate for porcelain shrinkage, porcelain powder was applied larger than the desired size by one-fifth. The porcelain was applied on the zirconia coping incrementally. The entire thickness of porcelain veneering was 1.25 mm before baking. The first layer applied on the zirconia was dentin porcelain, which determines the main color of the tooth. After baking this layer, enamel porcelain was applied as the second layer, which is responsible for translucency and anatomical form of the crown

(Figure 2f). This layer was also baked. Finally, glazing was performed. The internal porcelain surface was then sandblasted to increase retention, and was sent to the clinic for delivery [10] (Figure 2g).

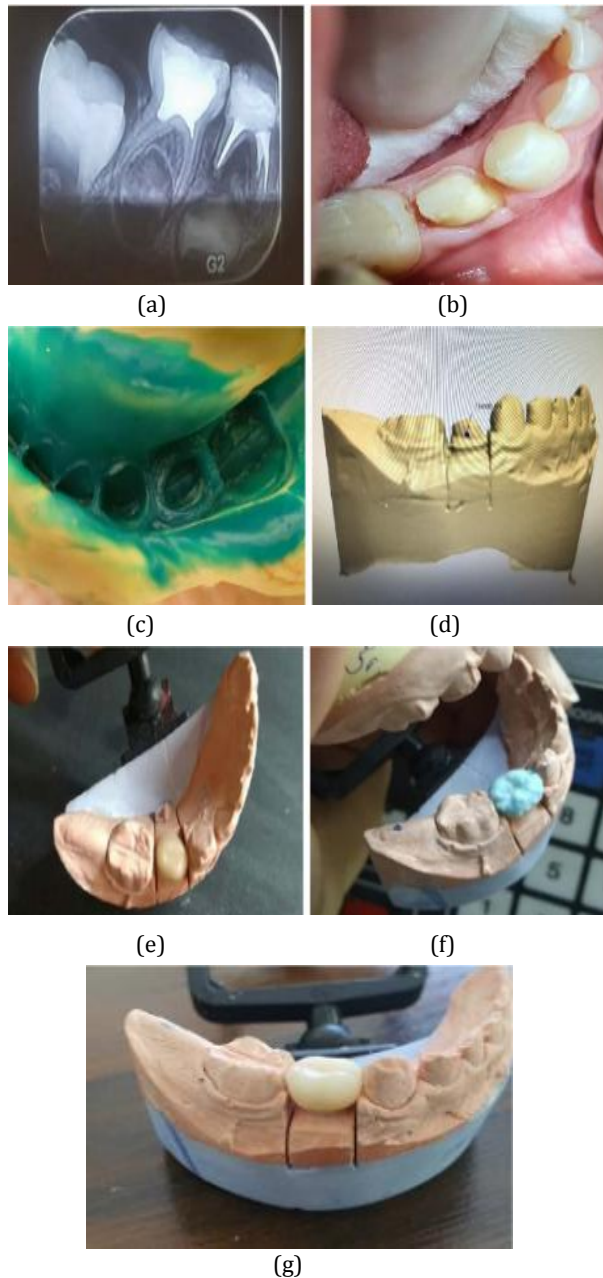


Fig. 2. (a) Radiograph and (b) intraoral photograph of primary first molar after pulpectomy; (c) a putty-wash impression was made from the mandibular arch; (d) cast scanned by a 3D scanner, (e) zirconia coping, (f) after applying layers of opaque porcelain on zirconia coping and (g) zirconia crown after glazing

Try-in and cementation of the crown:

The crown was first tried-in to assess its adaptation. A thin layer of Z-Prime (Z-Prime TM Plus, Bisco, USA) was applied on the zirconia crown's internal surface and allowed to dry for 3-5 minutes. Evidence shows that products containing 10-methacryloyloxydecyl dihydrogen phosphate (10-MDP) such as Z-Prime significantly increase the shear bond strength of zirconia crowns [11]. TheraCem dual-cure, self-etch cement (BISCO, Schaumburg, IL, USA) was used to cement the crown. The tooth was rinsed and dried. The cement was applied to the internal crown surface, and the crown was seated on the tooth. After 2-3 seconds, the buccal and lingual margins were light-cured (Flashlite 2.0, Medical Expo, USA), and excess cement was removed (Figure 3). The entire crown was then light-cured for 20-30 seconds. Since the selected cement was dual-cure, occlusion was rechecked after cementation [12].

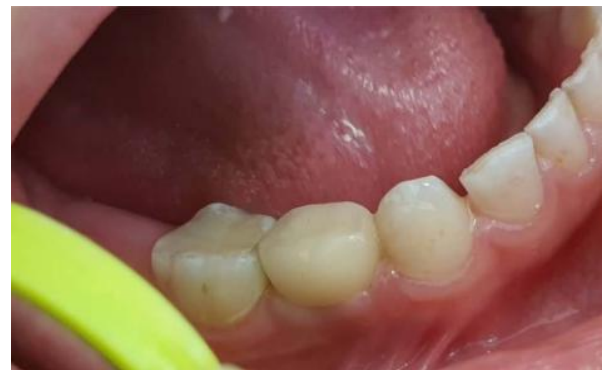

Fig. 3. Photograph of the tooth after cementation

Discussion

The use of SSCs for primary molars with extensive caries is a routine treatment procedure. These crowns enable tooth reconstruction without secondary caries development [2]. Unaesthetic appearance and risk of gingival irritation due to the release of nickel and chromium ions (that cause cytotoxic and hypersensitivity reactions) are among the drawbacks of

these crowns. In 2010, prefabricated zirconia crowns were proposed for primary teeth [6]. Zirconia is the crystalline oxide of zirconium with properties close to metals but with a color resembling natural teeth [13]. Zirconia crowns are a more esthetic treatment option than SSCs and can replace them [6]. Zirconia is a suitable dental material due to optimal properties such as favorable dimensional and chemical stability, optimal mechanical properties and hardness, and an elasticity coefficient similar to that of stainless steel alloys. Optimal flexural strength is another important zirconia property, ranging from 900 to 1200 MPa [14]. One drawback of zirconia crowns is that they require tooth preparation greater than that required for the placement of SSCs. Thus, tooth preparation for zirconia crowns is time-consuming. Gingival bleeding also causes discomfort and inflammation, and may prevent optimal setting of the cement [15]. Zirconia crowns cannot be crimped. Thus, instead of adapting and adjusting the zirconia crowns with the tooth, clinicians should prepare the tooth to fit the crown well. Thus, achieving maximum adaptation and retention in prefabricated zirconia crowns is difficult [1].

Amiri Daneshvar et al. [16] evaluated three techniques of veneering of zirconia copings. They compared three methods of manual incremental porcelain application, veneering with indirect composite, and use of CAD/CAM ceramic veneer to achieve optimal esthetics and translucency in zirconia copings. They observed that incremental porcelain application increased the fracture resistance of zirconia crowns. Similarly, porcelain was incrementally applied in our study to achieve optimal translucency and esthetics. Larsson and Wennerberg [17] evaluated the clinical efficacy of porcelain-fused-to-zirconia crowns for permanent teeth. They

concluded that these crowns had a clinical efficacy comparable to that of metal-ceramic crowns, which are still the gold standard for permanent teeth. To date, no study has evaluated the efficacy of these crowns for primary teeth. In the present study, the zirconia-based crown showed acceptable clinical efficacy after a 1-year follow-up.

Zirconia crowns have optimal biocompatibility. Also, the smooth and polished surface of zirconia minimizes plaque retention and subsequent gingival irritation. Taran and Kaya [18] demonstrated that zirconia crowns were superior to SSCs in gingival health and plaque accumulation, and had a better performance in the first two years after their placement. In the present case report, plaque accumulation was not seen on the crown after 6 months.

Evidence shows that the fracture and chipping rate of the porcelain veneering of zirconia crowns is higher than that of metal-ceramic crowns. Although the survival rate of zirconia crowns is over 90%, chipping of porcelain veneers has been reported as the most common technical problem [19]. In our study, porcelain fracture did not occur during the 1-year follow-up period. However, longer follow-ups are required to cast a final judgment in this respect.

In the present case report, the zirconia crown was first selected to restore the tooth since the parents required an esthetic restoration for the tooth after pulpectomy. However, since the size of the available prefabricated zirconia crowns did not match the respective tooth's size, a CAD/CAM zirconia crown was fabricated after making an impression from the mandibular arch to achieve optimal retention and adaptation. It was then veneered with feldspathic porcelain to achieve maximum esthetics and translucency.

The low chemical adhesion of zirconia crowns

crowns is due to their non-polar surface, which prevents their bonding to cement. Acidic monomers containing 10-MDP can be used to create a durable and robust bond [20]. Thus, Z-Prime was applied on the internal surface of the zirconia crown to increase the bond strength. Evidence shows that products containing 10-MDP such as Z-Prime significantly increase the shear bond strength of zirconia crowns. Phosphate monomers can form a chemical bond to the zirconia surface. They can also form a chemical bond to the terminal groups of polymerizing resins. Primers containing 10-MDP provide adhesion, are easy to apply, and do not require specific equipment [11]. Resin cements are preferred to conventional cements such as zinc phosphate and glass ionomer due to higher retention, fracture resistance, and marginal seal [21]. Also, since TheraCem (a type of self-etch cement) has a pH of around 4, it does not require etching and bonding. Thus, it accelerates the procedure and decreases the procedural steps, which is a tremendous advantage in pediatric dentistry [22].

One drawback of zirconia crowns is that they require tooth preparation greater than that required for the placement of SSCs. Thus, tooth preparation for zirconia crowns is time-consuming. Gingival bleeding also causes discomfort and inflammation, and may prevent the cement's optimal setting [15].

Conclusion

At present, SSCs are less popular due to the increased demand for esthetics. Many attempts have been made to improve the esthetic appearance and translucency of full-coverage restorations. In this case presentation, zirconia coping was veneered with feldspathic porcelain to achieve optimal esthetics. These crowns have favorable esthetics and performance. However, studies regarding their

efficacy in pediatric dentistry are limited. Therefore, further studies with longer follow-ups are required on their extensive applications in pediatric dentistry.

References

1. Lee JH. Guided tooth preparation for a pediatric zirconia crown. *J Am Dent Assoc.* 2018 Mar;149(3):202-8.e2.
2. Lopez Cazaux S, Hyon I, Prud'homme T, Dajeau Trudaud S. Twenty-nine-month follow-up of a paediatric zirconia dental crown. *BMJ Case Rep.* 2017 Jun 14;2017:bcr2017219891.
3. Planells del Pozo P, Fuks AB. Zirconia crowns--an esthetic and resistant restorative alternative for ECC affected primary teeth. *J Clin Pediatr Dent.* 2014 Spring;38(3):193-5.
4. Ha S-R, Kim S-H, Lee J-B, Han J-S, Yeo I-S, Yoo S-H. Effects of coping designs on stress distributions in zirconia crowns: Finite element analysis. *Ceram Int.* 2016 Mar ;42(4):4932-40.
5. Ioannidis A, Bindl A. Clinical prospective evaluation of zirconia-based three-unit posterior fixed dental prostheses: Up-to ten-year results. *J Dent.* 2016 Apr;47:80-5.
6. Mourouzis P, Arhakis A, Tolidis K. Computer-aided Design and Manufacturing Crown on Primary Molars: An Innovative Case Report. *Int J Clin Pediatr Dent.* 2019 Jan-Feb;12(1):76-9.
7. Santos GC Jr, Santos MJ Jr, Rizkalla AS, Madani DA, El-Mowafy O. Overview of CEREC CAD/CAM chairside system. *Gen Dent.* 2013 Jan-Feb;61(1):36-40.
8. Cho H, Won H, Choe H, Son M. Fracture characteristics of dental ceramic crown according to zirconia coping design. *procedia Eng.* 2011 Jun;10:1561-6.
9. Winter R. Posterior Full-contour Zirconia Crowns: Preparation Design. Available from: <https://www.Speareducation.com/spear-review/2012/10/posterior-full-contour-zirconia-crowns-preparation-design>.
10. Paek J, Noh K, Pae A, Lee H, Kim HS. Fabrication of a CAD/CAM monolithic zirconia crown to fit an existing partial removable dental prosthesis. *J Adv Prosthodont.* 2016 Aug; 8(4):329-32.
11. Yue X, Hou X, Gao J, Bao P, Shen J. Effects of MDP-based primers on shear bond strength between resin cement and zirconia. *Exp Ther Med.* 2019 May;17(5):3564-72.
12. Jivanescu A, Miglionico A, Barua S, Hategan SI. Alternative prosthodontic-based treatment of a patient with hypocalcified type Amelogenesis Imperfecta. *Clin Case Rep.*

2017 May 23;5(7):1093-7.

13. Abdulhadi B, Abdullah M, Alaki S, Alamoudi N, Attar M. Clinical evaluation between zirconia crowns and stainless steel crowns in primary molars teeth. *J Pediatr Dent*. 2017 Jan;5(1):21-7.

14. Daou EE. The zirconia ceramic: strengths and weaknesses. *Open Dent J*. 2014 Apr 18;8:33-42.

15. Clark L, Wells MH, Harris EF, Lou J. Comparison of Amount of Primary Tooth Reduction Required for Anterior and Posterior Zirconia and Stainless Steel Crowns. *Pediatr Dent*. 2016 Jan-Feb;38(1):42-6.

16. Amiri Daneshvar F, Alvaz Ah, Ahmadizenouz G, Bijani A. Effect of three veneering techniques on fracture resistance and marginal adaptation of zirconia -based crowns. *Caspian J Dent Res* 2020; 9:16 -25.

17. Larsson C, Wennerberg A. The clinical success of zirconia-based crowns: a systematic review. *Int J Prosthodont*. 2014 Jan-Feb;27(1):33-43.

18. Taran PK, Kaya MS. A Comparison of Periodontal Health

in Primary Molars Restored with Prefabricated Stainless Steel and Zirconia Crowns. *Pediatr Dent*. 2018 Sep 15;40(5):334-9.

19. Cantner F, Cacaci C, Mücke T, Randelzhofer P, Hajtó J, Beuer F. Clinical performance of tooth- or implant-supported veneered zirconia single crowns: 42-month results. *Clin Oral Investig*. 2019 Dec;23(12):4301-9.

20. Lim MJ, Yu MK, Lee KW. The effect of continuous application of MDP-containing primer and luting resin cement on bond strength to tribochemical silica-coated Y-TZP. *Restor Dent Endod*. 2018 Apr 3;43(2):e19.

21. Ahn JS, Yi YA, Lee Y, Seo DG. Shear Bond Strength of MDP-Containing Self-Adhesive Resin Cement and Y-TZP Ceramics: Effect of Phosphate Monomer-Containing Primers. *Biomed Res Int*. 2015;2015:389234.

22. Chen L, Yang J, Wang JR, Suh BI. Physical and biological properties of a newly developed calcium silicate-based self-adhesive cement. *Am J Dent*. 2018 Apr;31(2):86-90.