



## Vascular Endothelial Growth Factor Expression in Oral Lichen Planus: A Comparative Study

S Farhadi <sup>1</sup>, M Ghorbanpour <sup>1</sup>, F Pourabed <sup>2\*</sup>, A Lotfi <sup>3</sup>

<sup>1</sup>Assistant Professor, Oral & Maxillofacial Pathology Dept, Dental Branch of Tehran, Islamic Azad University, Tehran, Iran.

<sup>2</sup> Dentist

<sup>3</sup>Assistant professor, Oral & Maxillofacial Pathology dept., Dental faculty, Shahid Beheshti University of Medical Sciences, Tehran, Iran.

### ARTICLE INFO

#### Article Type

Original Article

#### Article History

Received: Nov 2017

Accepted: Dec 2017

ePublished: Jan 2018

#### Keywords:

Oral Lichen Planus,  
Vascular Endothelial  
Growth Factor,  
Immunohistochemistry,  
Angiogenesis

### ABSTRACT

**Background and aim:** Lichen planus (LP) is a chronic inflammatory disease with an uncertain pathogenicity. Recent reports have revealed that angiogenesis is effective in the pathogenesis and biologic behavior of lesions. Considering the limitations of the studies related to angiogenesis in oral LP (OLP) and the controversial results, the present study aimed to compare the expression of vascular endothelial growth factor (VEGF) in OLP and normal mucosa.

**Materials and methods:** In this case-control study, 4- $\mu$ m sections were prepared from selected OLP (erosive type) blocks and normal mucosa samples for immunohistochemistry (IHC) staining with VEGF marker. VEGF expression was quantitatively assessed via counting the positive-stained cells. The mean percentages of positive-stained cells in each sample were categorized in three groups: score 0 (the presence of 10% or lower), score 1 (the presence of 10% to 50%), and score 2 (the presence of more than 50% of stained cells). T-test and Mann-U-Whitney test were used for statistical analyses.

**Results:** The mean percentage of VEGF expression was 39.8% in 35 OLP samples, and 20.5% in 20 normal mucosa samples. Twenty OLP samples (57%) had score 1, and 15 (43%) had score 2. Eighteen normal mucosa samples (90%) had score 1, and two (10%) had score 2. Also, score 0 was not reported in any of the samples. The percentages of VEGF expression in OLP and normal mucosa did not show any statistically significant differences ( $P=0.5$ ). However, there was a significant difference between OLP and normal mucosa in VEGF expression score ( $P=0.012$ ), and OLP samples had significantly higher scores.

**Conclusion:** According to the results, VEGF expression in erosive OLP samples was significantly higher than that in normal mucosa.

Please cite this paper as: Farhadi S, Ghorbanpour M, Pourabed F, Lotfi A. Vascular Endothelial Growth Factor Expression in Oral Lichen Planus: A-Comparative Study. J Res Dent Maxillofac Sci. 2018;3(1):1-5.

## Introduction:

In general, angiogenesis participates in several pathophysiologic processes.<sup>(1)</sup> This process has an important role in physiologic conditions such as fetal development and wound healing, and in pathologic conditions such as tumoral growth, metastasis, and the development of inflammatory diseases.<sup>(2)</sup> In some studies, increased angiogenesis has been reported in malignancies and in more aggressive pathologic lesions, and nowadays, new treatments have been based on inhibiting or at least restricting this phenomenon.<sup>(3-6)</sup>

Among important angiogenesis-stimulating factors, vascular endothelial growth factor (VEGF) has been identified as one of the most important mediators, and the expression of VEGF marker has been used to assess the level of angiogenesis in pathologic lesions. VEGF is a multifunctional cytokine which is expressed in different conditions such as increased vascular permeability and angiogenesis, and it stimulates the proliferation and migration of endothelial cells and increases vascular permeability.<sup>(7)</sup> This cytokine is released by different cell types and acts as the main regulator of physiologic and pathologic angiogenesis.<sup>(8,9)</sup> In some studies, the expression of VEGF marker has been used to assess microvessel density in pathologic lesions.<sup>(10,11)</sup> For example, it has been shown that when VEGF is overexpressed, it can cause vascular diseases in the retina and other body parts. Solid cancerous tumors cannot grow and metastasize without adequate blood supply; however, the cancers that can express VEGF are able to grow and metastasize.<sup>(12,13)</sup>

Despite several studies, the pathogenicity of oral lichen planus (OLP) is still unclear.<sup>(14)</sup> In some references, this disease has been introduced as a T-cell-mediated autoimmune disease which affects the skin and mucosa. In other studies, stress, genetic background, and other factors have also been mentioned in its etiology.<sup>(15)</sup> In a study by Scardina et al, a significant increase in angiogenesis has been reported in OLP patients in comparison with normal mucosa.<sup>(16)</sup> However, there are no definitive conclusions on this topic or about its effect on the pathogenesis and

treatment process of this disease in the references. Accordingly, considering the limitations of previous studies in this regard and the controversies in the obtained results, the present study aimed to compare the expression of VEGF marker in OLP samples and normal mucosa samples at the oral and maxillofacial pathology department of the dental branch of Islamic Azad University of Tehran during 2006-2017.

## Materials and Methods:

The present study was performed via the selection of OLP samples from the archives of the oral and maxillofacial pathology department of the dental branch of Islamic Azad University of Tehran with definitive microscopic diagnoses (all the samples had been registered as the erosive type based on the clinical and microscopic findings), and samples of normal mucosa without any pathologic lesion, referred for oral surgeries for reasons other than pathology were also selected.

From the selected blocks, 4- $\mu$ m sections were prepared for hematoxylin and eosin (H&E) staining. After reexamining the related slides by an oral and maxillofacial pathologist, slides with adequate tissue and proper fixation were selected. Samples with bleeding or inadequate tissue were excluded. Afterwards, for immunohistochemistry (IHC) staining with VEGF marker, 4- $\mu$ m sections were prepared. The mentioned sections were first immersed in xylene to remove the paraffin (de-wax) and then in graded alcohols to dehydrate. To inhibit the peroxide activity, the samples were placed in 3% hydrogen peroxide (H<sub>2</sub>O<sub>2</sub>) with phosphate buffer. The antigen retrieval process was performed in a microwave under the pressure of 2 atmospheres (atm) at 120°C for 10 minutes with exposure to the primary antibody with Anti-VEGF for 30 minutes and then to secondary antibody (15 minutes), DAB (staining reaction), and Mayer's hematoxylin (background staining). The samples were placed in phosphate buffer after each stage.

The assessment of blood vessels was performed according to the method described by Rubini et al.<sup>(17)</sup> In brief, the VEGF expression in

five random fields at 400× magnification was calculated as the mean percentage of VEGF expression in epithelial cells, fibroblasts, and inflammatory cells, and the results were divided into three groups as follows:

Score 0: the presence of 10% or less positive-stained cells

Score 1: the presence of 10% to 50% positive-stained cells

Score 2: the presence of more than 50% positive-stained cells

In order to compare the expression of this marker more comprehensively, both quantitative (with regard to the mean percentage of positive-stained cells) and qualitative (with regard to the expression score of the marker) comparisons were made. To compare the percentage of the positive-stained cells in the two studied groups, T-test was used. Mann-U-Whitney test was used to compare the expression score of VEGF marker in the two studied groups.

Figures 1 to 3 show the expression of VEGF in the microscopic sections of OLP samples.

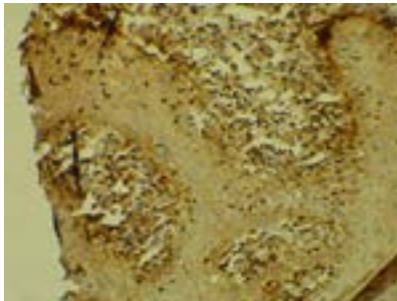


Figure 1: VEGF expression in the microscopic view of OLP (score 2) at 200× magnification

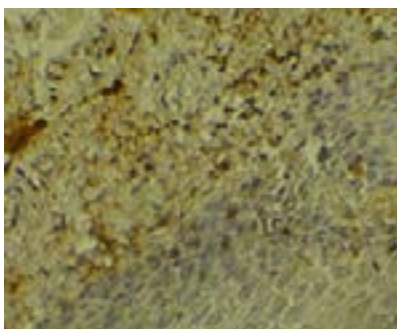


Figure 2: VEGF expression in the microscopic view of OLP (score 1) at 200× magnification




Figure 3: VEGF expression in the microscopic view of OLP (score 1) at 100× magnification

**Result:**

After IHC staining, the obtained results related to 55 studied samples including 38 females and 17 males with the mean age of 39.2±8.3 years are as follows: the lowest percentage of VEGF expression in 35 OLP samples (erosive type) was 12%, and the highest percentage was 62% with the mean percentage of VEGF expression equal to 39.8±11%. The lowest percentage of VEGF expression in normal mucosa samples was 11%, and the highest percentage was 95% with the mean percentage of VEGF expression equal to 20.5±26.3%.

T-test was used to compare the percentage of VEGF expression in OLP and normal mucosa. According to this test, the percentage of VEGF expression showed no significant statistical difference between OLP and normal mucosa (P=0.05).

Table 1 shows the score of VEGF nuclear expression.

**Table 1: Comparison of VEGF score in OLP and normal mucosa**

	VEGF score			Total
	0	1	2	
OLP	0	20 (57%)	15 (43%)	35
Normal mucosa	0	18 (90%)	2 (10%)	20

VEGF=Vascular Endothelial Growth Factor, OLP=Oral Lichen Planus

According to Mann-U-Whitney test, there was a significant statistical difference between OLP and normal mucosa in terms of the VEGF expression score (P=0.012), and OLP samples

had significantly higher VEGF expression scores compared to normal mucosa.

### Discussion:

The results of the present study showed that there is a statistically significant difference between OLP and normal mucosa in terms of the VEGF score, and OLP samples showed a significantly higher VEGF expression score in comparison with normal mucosa.

In line with our study, Tao et al showed that VEGF expression has been significantly higher in atrophic-erosive OLP in comparison with reticular and control samples.<sup>(18)</sup> Moreover, Scardina et al reported that VEGF expression in OLP samples is significantly higher compared to normal mucosa.<sup>(16)</sup> Notwithstanding, contrary to the results of the present study, Ding et al showed that VEGF expression had been lower in OLP than in normal mucosa.<sup>(19)</sup>

Also, Výbohová et al reported that in cutaneous LP (CLP) patients, both vascular bed and VEGF expression had increased significantly compared to healthy samples,<sup>(20)</sup> and VEGF expression in cutaneous ulcers was significantly higher in the epidermis than in the dermis. These findings indicated the correlation between angiogenesis and the pathogenesis of CLP in the mentioned study.<sup>(20)</sup>

Mardani et al stated that in OLP patients, in comparison with the controls, the level of serum VEGF has been significantly higher.<sup>(21)</sup> In general, angiogenesis is vital during fetal development, and after this period, it participates in several pathophysiologic processes.<sup>(1)</sup> This process has a significant role in physiologic conditions such as fetal development and wound healing and also in pathologic conditions such as tumoral growth, metastasis, and the progression of inflammatory diseases.<sup>(2)</sup>

Among important stimulating factors of endothelial growth, VEGF has been identified as the most important angiogenic mediator. This GF is a multifunctional cytokine which is expressed in different conditions such as increased vascular permeability and angiogenesis, and it stimulates the proliferation and migration of endothelial cells and increases vascular permeability.<sup>(7)</sup> This cytokine is released by different types of cells and acts as a key regulator

of physiologic and pathologic angiogenesis.<sup>(8,9)</sup> In some studies, the expression of VEGF marker has been used to assess microvessel density in pathologic lesions.<sup>(10,11)</sup> Also, it has been shown that the cancers that can express VEGF can grow and metastasize.<sup>(12,13)</sup>

During inflammation or hypoxia, VEGF is expressed in some cells such as keratocytes, activated macrophages, and hepatocytes. The important role of VEGF in numerous biologic processes such as tumorigenesis and wound healing has been assessed.<sup>(22)</sup> Also, the VEGF-induced angiogenesis has been shown in the pathogenesis of some diseases such as autoimmune or inflammatory diseases including periodontal diseases, psoriasis, osteoarthritis, rheumatoid arthritis (RA), multiple sclerosis (MS), and inflammatory bowel disease (IBD).<sup>(23-29)</sup>

Despite several studies, the pathogenicity of LP has not been fully understood.<sup>(14)</sup> The scientific references have not rendered comprehensive and precise reports regarding the role of angiogenesis in the pathogenesis of this disease although according to these studies, OLP as a chronic autoimmune disease with an inflammatory origin, has necessary scientific evidence regarding the presence of hypoxia induced by inflammatory cells, expression of VEGF, and the initiation of the consequent angiogenesis process.<sup>(30)</sup>

Thus, considering the mentioned inflammatory etiology for OLP and also the presence of a positive correlation based on the development of inflammation-induced angiogenesis and facilitation of inflammation in the presence of angiogenesis, the results of the recent study may also confirm the results of the mentioned reports. However, in order to find clinical implications for the results of the recent fundamental studies, future clinical trials on the effect of antiangiogenic drugs on the development or suppression of OLP are recommended.

### Conclusion:

The results of the present study indicated that VEGF expression in erosive OLP samples was significantly higher than that in normal mucosa

### Acknowledgement:

This article is derived from the student thesis No#25552 registered at the dental branch of Islamic Azad University of Tehran.



## References:

1. Carmeliet P. Angiogenesis in health and disease. *Nat Med.* 2003 Jun;9(6):653-60.
2. Liekens S, De Clercq E, Neyts J. Angiogenesis: regulators and clinical applications. *Biochem Pharmacol.* 2001 Feb 1;61(3):253-70.
3. Seifi S, Shafaie S, Ghadiri S. Microvessel density in follicular cysts, keratocystic odontogenic tumors and ameloblastomas. *Asian Pac J Cancer Prev.* 2011;12(2):351-6.
4. Shahsavari F, Farhadi S, Sadri D, Sedehi M. Evaluation of Microvasculature by CD34 Expression in Esophagus and Oral Squamous Cell Carcinoma. *J Contemp Dent Pract.* 2015 Jun 1;16(6):458-62.
5. Sadri D, Shahsavari F, Farhadi S, Shahabi Z, Mehran Z. Angiogenesis concept in odontogenic keratocyst: A comparative study. *Indian J Dent Res.* 2017 May-Jun;28(3):275-80.
6. Sargolzaei S, Farhadi S, Kazemi B, Bandehpour M, Kharazifard MJ. The correlation between p16 expression and INK4a locus mutation with grades and stages in oral squamous cell carcinoma. *Indian J Pathol Microbiol.* 2014 Jan-Mar;57(1):24-30.
7. Folkman J. Angiogenesis in cancer, vascular, rheumatoid and other disease. *Nat Med.* 1995 Jan;1(1):27-31.
8. Brown LF, Detmar M, Claffey K, Nagy JA, Feng D, Dvorak AM, et al. Vascular permeability factor/vascular endothelial growth factor: a multifunctional angiogenic cytokine. *EXS.* 1997;79:233-69.
9. Ferrara N, Davis-Smyth T. The biology of vascular endothelial growth factor. *Endocr Rev.* 1997 Feb;18(1):4-25.
10. Leonardi R, Caltabiano M, Pagano M, Pezzuto V, Loreto C, Palestro G. Detection of vascular endothelial growth factor/vascular permeability factor in periapical lesions. *J Endod.* 2003 Mar;29(3):180-3.
11. Sadri D, Farhadi S, Shahabi Z, Sarshar S. Expression of Vascular Endothelial Growth Factor in Odontogenic Cysts: Is There Any Impression on Clinical Outcome? *Open Dent J.* 2016 Dec 30;10:752-9.
12. Mitrou GK, Tosios KI, Kyroudi A, Sklavounou A. Odontogenic keratocyst expression vascular endothelial growth factor: an immunohistochemical study. *J Oral Pathol Med.* 2009 May;38(5):470-5.
13. Cooper ME, Vranes D, Youssef S, Stacker SA, Cox AJ, Rizkalla B, et al. Increased renal expression of vascular endothelial growth factor (VEGF) and its receptor VEGFR-2 in experimental diabetes. *Diabetes.* 1999 Nov;48(11):2229-39.
14. Tampa M, Caruntu C, Mitran M, Mitran C, Sarbu I, Rusu LC, et al. Markers of Oral Lichen Planus Malignant Transformation. *Dis Markers.* 2018 Feb 26;2018:1959506.
15. Mittal N, Shankari GM, Palaskar S. Role of angiogenesis in the pathogenesis of oral lichen planus. *J Oral Maxillofac Pathol.* 2012 Jan;16(1):45-8.
16. Scardina GA, Ruggieri A, Messina P, Maresi E. Angiogenesis of oral lichen planus: a possible pathogenetic mechanism. *Med Oral Patol Oral Cir Bucal.* 2009 Nov 1;14(11):e558-62.
17. Rubini C, Artese L, Zizzi A, Fioroni M, Ascani G, Goteri G, et al. Immunohistochemical expression of vascular endothelial growth factor (VEGF) in different types of odontogenic cysts. *Clin Oral Investig.* 2011 Oct;15(5):757-61.
18. Tao X, Huang Y, Li R, Qing R, Ma L, Rhodus NL, et al. Assessment of local angiogenesis and vascular endothelial growth factor in patients with atrophic-erosive and reticular oral lichen planus. *Oral Surg Oral Med Oral Pathol Oral Radiol Endod.* 2007 May;103(5):661-9.
19. Ding M, Xu JY, Fan Y. Altered expression of mRNA for HIF-1alpha and its target genes RTP80I and VEGF in patients with oral lichen planus. *Oral Dis.* 2010 Apr;16(3):299-304.
20. Výbohá D, Mellová Y, Adamicová K, Adamkov M, Hešková G. Quantitative immunohistochemical assessment of blood and lymphatic microcirculation in cutaneous lichen planus lesions. *Histol Histopathol.* 2015 Jun;30(6):697-706.
21. Mardani M, Ghabanchi J, Fattahi MJ, Tadbir AA. Serum level of vascular endothelial growth factor in patients with different clinical subtypes of oral lichen planus. *Iran J Med Sci.* 2012 Dec;37(4):233-7.
22. Ferrara N, Gerber HP, LeCouter J. The biology of VEGF and its receptors. *Nat Med.* 2003 Jun;9(6):669-76.
23. Cornellini R, Artese L, Rubini C, Fioroni M, Ferrero G, Santinelli A, et al. Vascular endothelial growth factor and microvessel density around healthy and failing dental implants. *Int J Oral Maxillofac Implants.* 2001 May-Jun;16(3):389-93.
24. Creamer D, Sullivan D, Bicknell R, Barker J. Angiogenesis in psoriasis. *Angiogenesis.* 2002;5(4):231-6.
25. Bonnet CS, Walsh DA. Osteoarthritis, angiogenesis and inflammation. *Rheumatology (Oxford).* 2005 Jan;44(1):7-16.
26. Szekanecz Z, Besenyi T, Paragh G, Koch AE. Angiogenesis in rheumatoid arthritis. *Autoimmunity.* 2009 Nov;42(7):563-73.
27. Kirk S, Frank JA, Karlik S. Angiogenesis in multiple sclerosis: is it good, bad or an epiphenomenon? *J Neurol Sci.* 2004 Feb 15;217(2):125-30.
28. Watanabe H, Mamelak AJ, Wang B, Howell BG, Freed I, Esche C, et al. Anti-vascular endothelial growth factor receptor-2 (Flk-1/KDR) antibody suppresses contact hypersensitivity. *Exp Dermatol.* 2004 Nov;13(11):671-81.
29. Koutroubakis IE, Xiadakis C, Karmiris K, Sfridakis A, Kandidaki E, Kouroumalis EA. Serum angiogenin in inflammatory bowel disease. *Dig Dis Sci.* 2004 Nov-Dec;49(11-12):1758-62.
30. Scardina GA, Picone V, Cacioppo A, Messina P. Study of microcirculation in oral lichen planus by video-capillaroscopy. *Oral Surg Oral Med Oral Pathol Oral Radiol Endod.* 2007 Apr;103(4):e30-4.