



A Rare Odontogenic Tumor Known as Cementoblastoma; A Case Report

Jolehar M^{1*}, Khalili M², Baghaee F³

¹Assistant professor, Oral and Maxillofacial Pathology Dept, Dental Branch of Tehran, Islamic Azad University, Tehran, Iran.

²Assistant professor, Oral and Maxillofacial Pathology Dept, Faculty of Dentistry, Tehran University of Medical Sciences, Tehran, Iran.

³Associate Professor, Oral and Maxillofacial Pathology Dept, Faculty of Dentistry, Tehran University of Medical Sciences, Tehran, Iran.

ARTICLE INFO

Article Type
Case Report

Article History

Received: Oct 2016

Accepted: January 2016

ePublished: March 2016

Keywords:

Odontogenic tumor,
Mesenchyme,
Neoplasm

ABSTRACT

Background: Odontogenic tumors are derived from the epithelial and/or mesenchymal remnants of the tooth-forming apparatus. Therefore, they are found exclusively in tooth-bearing areas. Similar to other neoplasms in the body, odontogenic tumors tend to histologically mimic the cell or tissue of origin.

Case Report: A 5-year-old boy presented with a chief complaint of pain in the mandible which started 3 months ago. Oral examination revealed bony expansion and a radiopaque mass fused with the roots of deciduous second molar was detected during radiographic examination. After surgical excision of the lesion and the involved tooth, microscopic examination revealed neoplastic tissue consisted of trabeculae of mineralized material with irregular lacunae and prominent basophilic reversal lines. Each trabecula was lined by prominent cells surrounded by cellular connective tissue. The lesion infiltrated the pulp chamber and root canals.

Conclusion: According to the clinical and radiographic findings, bone-producing tumors, odontogenic tumors with calcifications and reactive lesions were included in the differential diagnosis. However, based on histopathology and radiographic data, final diagnosis of Cementoblastoma, a benign odontogenic tumor, was confirmed. Patient follow-up revealed no recurrence of the lesion.

Please cite this paper as:

Jolehar M, Khalili M, Baghaee F. A Rare Odontogenic Tumor Known as Cementoblastoma; A Case Report. J Res Dent Maxillofac Sci. 2016;1(2):41-45.

*Corresponding author:

Maryam Jolehar

Emails: joleharm@gmail.com

Introduction:

Odontogenic tumors comprise a heterogeneous group of lesions arising from tooth-forming tissues or their remnants. Therefore, they may histologically mimic the cells or tissues of origin, or may have an appearance similar to hard dental tissues such as enamel, dentin and cementum or soft tissues of enamel organ or dental pulp. These tumors must be considered in the differential diagnosis of the lesions that occur in the jaws. ⁽¹⁾ Benign Cementoblastoma (true Cementoma) is a rare cementum-producing odontogenic tumor with distinctive clinical and radiographic characteristics. It attaches to the roots of posterior mandibular teeth and grows gradually, causing expansion of the involved jaw. ⁽²⁾ Here, we present a case of rare benign Cementoblastoma. This odontogenic tumor rarely affects the deciduous teeth.

Case Report:

A 5-year-old boy was referred with a chief complaint of pain in the right quadrant of the mandible which started approximately 3 months ago. The patient had no significant past medical and/or dental history. Oral examination revealed hard bony expansion of the lower jaw with normal overlying mucosa. No cervical lymphadenopathy was detected. Dental radiographs showed a 1.4 cm radiopaque mass fused with the roots of deciduous second molar (Fig. 1). The opacity was surrounded by a relatively thin radiolucent rim (Fig. 2). The radiopaque mass obscured the root outline. According to the clinical and radiographic findings, bone-producing tumors, odontogenic tumors with calcifications and reactive lesions were included in the differential diagnosis.

An excisional biopsy was performed and the specimen was sent for histopathology assessment to the oral & maxillofacial pathology laboratory of Tehran University of Medical Sciences. The specimen included a tooth measuring 1cm mesiodistally and 0.8cm buccolingually with a creamy brownish osseous mass that covered the roots (Fig. 3). The specimen was placed in formalin fixed solution and acid before cutting. Histopathology assessment revealed neoplastic tissue

consisted of trabeculae of mineralized material with irregular lacunae and prominent basophilic reversal lines (Fig. 4&5). The spaces between the trabeculae contained cellular connective tissue. Each trabecula was lined by prominent cells. The periphery of the lesion was composed of fibro-vascular tissue matrix. The lesion infiltrated the pulp chamber and root canals. Based on the microscopic findings, the differential diagnoses included Osteoblastoma and Cementoblastoma, but based on the radiographic and microscopic evidences (fusion with the roots), final diagnosis of Cementoblastoma was confirmed. No evidence of recurrence was detected during 9-month patient follow-up.

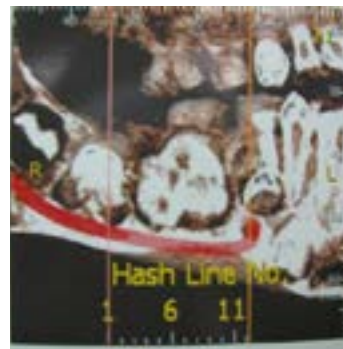


Figure 1- A radiopaque mass fused with the roots of deciduous second molar

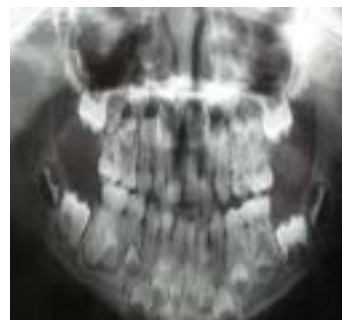

Figure 2. The opacity surrounded by a relatively thin radiolucent rim

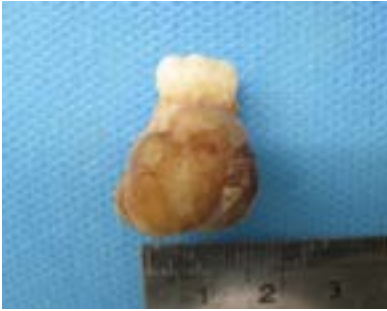


Figure 3- Deciduous second molar attached to a creamy brownish mass covering the roots

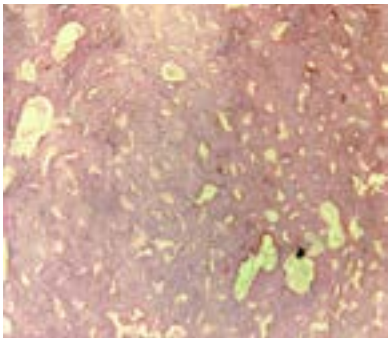


Figure 4- Trabeculae of mineralized material with irregular lacunae




Figure 5- Trabeculae of mineralized material with prominent basophilic reversal lines infiltrating the dentin

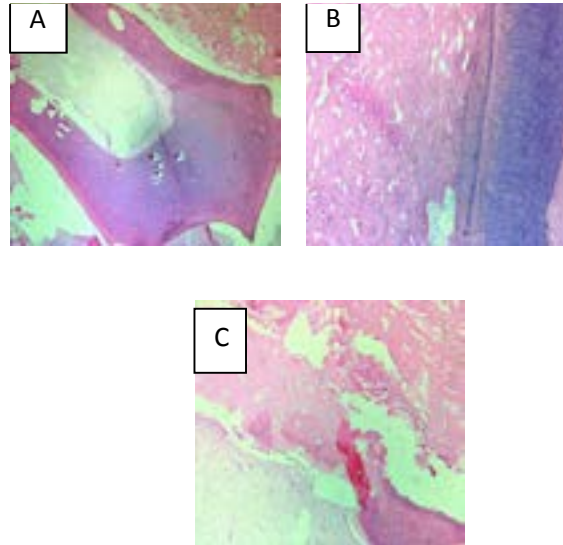


Figure 6- Tumor infiltrating the pulp chamber and root canal and replacing the dentin (A, B, C)

Discussion:

In the present case report, we discuss an unusual case of rare benign Cementoblastoma associated with a deciduous tooth.

Cementoblastoma was first described by Dewey in 1927.⁽³⁾ In the World Health Organization (WHO) classification of benign odontogenic tumors, this lesion is recognized as one of the cemental neoplasias.^(4, 5) Moreover, it is recognized as one of the four types of cementum-producing disorders in the WHO classification of periapical odontogenic tumors. The other three types of cementum-producing disorders are Periapical Cemental Dysplasia, Cementifying Fibroma and Gigantiform Familial Cementoma.⁽³⁾ Cementoblastomas are uncommon odontogenic tumors derived from neoplastic cementoblasts⁽⁶⁾ and are considered as true cementum neoplasms.⁽³⁾ Cementoblastoma is rare in the oral cavity and accounts for less than 1% of all odontogenic tumors and is currently classified by the 2005 WHO as an ectomesenchymal odontogenic tumor with or without odontogenic epithelium that originates from dental roots and is characterized by cementum formation.^(3, 4, 7, 8) Cementoblastoma or true Cementoma is a slow growing tumor mostly involving the permanent dentition. It is especially uncommon in children. Rare cases have occurred in primary dentition.^(3, 5, 9) It is more common in

patients under the age of 30 years.^(4, 8) The most common teeth involved by Cementoblastoma are mandibular first molars followed by mandibular premolars.^(3, 4, 5, 8) The tumor has been also associated with multiple teeth or impacted molars.^(5, 7) No significant sex predilection has been reported, however some authors have reported contradictory findings.⁽⁴⁾ The average tumor size is 2.1 cm.⁽⁹⁾ The mandible is three times more frequently involved than the maxilla.^(3, 4, 5, 9) The lesion is usually unilateral and asymptomatic and is discovered incidentally during routine radiographic examinations; however, pain and swelling have been reported.^(4, 5, 9, 10) Paresthesia of the lower lip and pathologic jaw fractures have been rarely reported.⁽⁶⁾ Localized cortical bone expansion and facial asymmetry are common.⁽⁴⁾ Cementoblastoma grows with unlimited potential and can be locally aggressive resulting in bony expansion, root resorption, displacement of adjacent teeth and jaw deformity. Recurrent tumors have shown high percentages of jaw expansion and cortical perforation.⁽⁵⁾ Radiographic view usually shows a well-defined radiopaque mass often fused with a dental root or roots encircled by a thin radiolucent rim with an outer cortical border.^(3, 4, 8, 10) This radiographic finding is almost pathognomonic.⁽⁸⁾ The root contour is obliterated due to fusion with tumor. Root resorption may occur.⁽⁵⁾ The internal structure of the mass may have a mixed radiolucent radiopaque density.⁽³⁾

The tumor grossly appears as a round to ovoid, well-circumscribed mass of hard and calcified tissue surrounding the root of the affected tooth.⁽⁸⁾ There are a few lesions which should be differentiated from this lesion such as Osteoma and Odontoma. Odontomas are usually not fused with the dental root and show a more heterogeneous radiopacity. Benign Osteoblastoma, Periapical Cemental Dysplasia, Familial Gigantiform Cementoma, Hypercementosis (a small lesion not associated with pain or jaw swelling), Chronic Focal Sclerosing Osteitis, Osteomyelitis and Osteosarcoma are other lesions included in the differential diagnoses.^(3, 4, 5, 8, 11) Radiographic and clinical findings can help distinguish these lesions. Osteoblastoma and Cementoblastoma are closely related lesions with similar histological views.⁽³⁾ Direct fusion with the radicular surface is the most significant microscopic finding that

helps differentiate Cementoblastoma and Osteoblastoma.⁽⁴⁾ Most teeth affected by the early stages of Cementoblastoma respond normally to vitality tests, but pulp necrosis can occur in later stages.⁽³⁾

The WHO defines Cementoblastoma as a neoplasm histologically characterized by the formation of cementum-like tissue with numerous reversal lines.^(2, 5) The present case also demonstrated this characteristic feature. The prominent basophilic reversal lines in the lesion may have a pagetoid appearance.^(2, 5, 8) Multinucleated osteoclastic giant cells and plump cementoblasts may be present in the interstitial fibrovascular stroma.^(5, 8) Histologically, fusion of the tumor with dental roots which is known as «replacement resorption» is a distinguishing feature.⁽⁶⁾

Treatment plan in most cases of odontogenic tumors is similar in children and adults. Considering the unlimited growth potential of this lesion, the usual treatment plan is complete surgical excision of the tumor and extraction of the affected teeth.^(4, 8, 9)

Recurrence is common with incomplete removal, and even higher in cases treated with surgical curettage alone.^(5, 8) The prognosis is usually excellent after appropriate treatment approaches.⁽⁵⁾

Conclusions:

Benign Cementoblastoma is a rare tumor of the jaw with distinctive radiographic and histological characteristics which involves mandibular premolars and molars. This benign tumor is extremely rare in the deciduous dentition and responds well to adequate surgical management.

Acknowledgement:

We are thankful to those who helped us in this article including research center of Islamic Azad University, Dental Branch of Tehran.

References:

1. Sekerci AE, Nazlım S, Etoz M, Deniz K, Yasa Y. Odontogenic tumors: A collaborative study of 218 cases diagnosed over 12 years and comprehensive review of the literature. *Med Oral Pathol Oral Cir Bucal* 2015;20:e34-44.
2. Aiyer RG, Rajagopal S. Benign Cementoblastoma—a rare odontogenic neoplasm. *Indian J otolaryngo and head and neck surg* 2000;52(3):272-3.

3. Kumar S, Prabhakar V, Angra R. Infected Cementoblastoma. *Nat J Maxillofac Surg* 2011;2(2):200-3.
4. Sumer M, Gunduz K, A. Sumer P, Gunhan O. Benign Cementoblastoma: A case report. *Med Oral Pathol Oral Cir Bucal* 2006;11(6):E483-5.
5. Sankari LS, Ramakrishnan K. Benign Cementoblastoma. *J Oral Maxillofac Pathol* 2011;15(3):358-60.
6. Bilodeau E, Collins B, Costello B, Potluri A. Case Report: a Pediatric Case of Cementoblastoma with Histologic and Radiographic Features of an Osteoblastoma and Osteosarcoma. *Head and Neck Pathol* 2010;4(4):324–8.
7. Iannaci G, Luise R, Iezzi G, Piattelli A, Salierno A. Multiple Cementoblastoma: A Rare Case Report. *Case Rep Dent* 2013:1-4.
8. Huber AR, Folk GS. Cementoblastoma. *Head and Neck Pathol* 2009; 3(2):133–5.
9. Harada H, Omura K, Mogi S, Okada N. Cementoblastoma Arising in the Maxilla of an 8-Year-Old Boy: A Case Report. *Int J Dent* 2011:1-4.
10. Sharma N. Benign Cementoblastoma: A rare case report with review of literature. *Contem Clin Dent* 2014;5(1):92-4.
11. Noffke CE, Ngwenya SP, Nzima N, Raubenheimer EJ, Rakgwale NB. Gigantiform cementoma in a child. *Dent maxillofac Radiol* 2012;41(3):264–6.