

# Successful Management of Rhinocerebral Mucormycosis in a Child with Uncontrolled Diabetes Mellitus and Recent Blindness: A Case Report

Hossein Daneste<sup>1</sup>, Niloofar Ghadimi<sup>2</sup>, Mohsen Mardani<sup>3</sup>, Shabnam Maleki<sup>4</sup>,  
Mohammad Hossein Anbardar<sup>5</sup>, Seyedeh Saba Sharifzadeh<sup>6</sup>  

<sup>1</sup> Department of Oral and Maxillofacial Surgery, Shiraz University of Medical Sciences, Shiraz, Iran

<sup>2</sup> Department of Oral and Maxillofacial Radiology, Faculty of Dentistry, Tehran Medical Sciences, Islamic Azad University, Tehran, Iran

<sup>3</sup> Department of Oral and Maxillofacial Surgery, Shiraz University of Medical Sciences, Shiraz, Iran

<sup>4</sup> Department of Pediatric Dentistry, Babol University of Medical Sciences, Babol, Iran

<sup>5</sup> Department of Pathology, Shiraz Medical School, Namazee Teaching Hospital, Shiraz University of Medical Science, Shiraz, Iran

<sup>6</sup> Department of Oral and Maxillofacial Medicine, Faculty of Dentistry, Tehran Medical Sciences, Islamic Azad University, Tehran, Iran

## Corresponding author:

Seyedeh Saba Sharifzadeh,  
Department of Oral and Maxillofacial Medicine, Faculty of Dentistry, Tehran Medical Sciences, Islamic Azad University, Tehran, Iran

sharifzadeh.saba@yahoo.com

## Article History

Received: 12 March 2021

Accepted: 30 June 2021

## Abstract

**Background and Aim:** Mucormycosis is an aggressive and life-threatening fungal infection that affects patients with uncontrolled diabetes mellitus (DM) or compromised immune system. The most common symptom of rhinocerebral mucormycosis is sinusitis, and if the infection spreads beyond the sinus, more severe symptoms such as blindness, seizure, and death may occur.

**Case Presentation:** We describe a case of rhinocerebral mucormycosis successfully treated in an 11-year-old boy with uncontrolled DM and neglected sinusitis with sudden blindness.

**Conclusion:** Patients with poorly controlled or insulin-dependent DM who experience periods of ketoacidosis are more likely to develop mucormycosis. Therefore, correct diagnosis and timely referral of patients greatly affect the prognosis of the disease and the treatment process.

**Key Words:** Blindness; Diabetes Mellitus; Mucormycosis; Sinusitis

**Cite this article as:** Sharifzadeh S, Daneste H, Ghadimi N, Mardani M, Maleki S, Anbardar MH. Successful Management of Rhinocerebral Mucormycosis in a Child with Uncontrolled Diabetes Mellitus and Recent Blindness: A Case Report.

**J Res Dent Maxillofac Sci. 2022; 7(2):98-103.**

## Introduction

Mucormycosis (zygomycosis) is an infection caused by a group of microorganisms known as Mucorales, including *Rhizopus*, *Mucor*, etc [1]. These organisms are opportunistic pathogens that are not commonly pathogenic to immunocompetent individuals and they are usually cultured from the nostrils, throat, and mouth in healthy people. However, in patients with compromised immune system, spores

may sometimes enter through the skin lesions caused by trauma or burns and cause disease [2]. Predisposing factors for mucormycosis include diabetes mellitus (DM) which accounts for about 40-50% of the cases, hematologic malignancies, long-term neutropenia, transplantation, malnutrition, etc [2,3]. Among all the manifestations of mucormycosis that have been reported so far, including cutaneous, gastrointestinal,

and respiratory manifestations, and the disseminated type, rhinocerebral manifestations are the most common. In the head and neck region, the disease develops in the oral cavity, nose, or sinuses, and eventually spreads to the brain, endangering the patient's life [2,4].

Herein, we report a patient with DM who was hospitalized with a chief complaint of bilateral ulcers around the nose, facial swelling, and loss of vision who was treated following a diagnosis of mucormycosis.

### Case Presentation

An 11-year-old boy presented to Namazee Hospital in Shiraz in April 2020 due to diabetic ketoacidosis. He was referred to the Oral and Maxillofacial Surgery Department of Shiraz Dental School with a complaint of bilateral ulceration and swelling of the sides of the nose. The onset of ulceration in the right side of the nose was reported to be earlier than the left side.

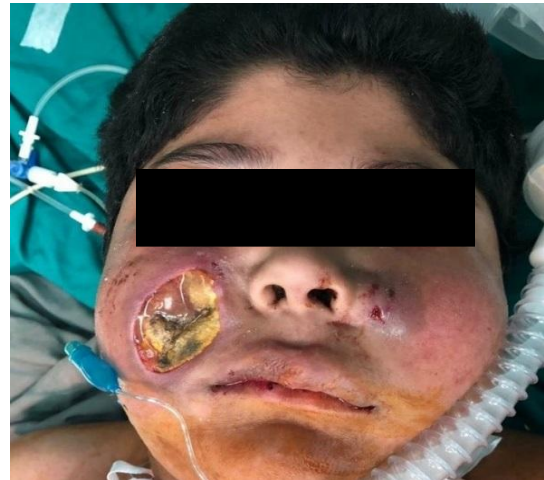On general examination, the patient had no fever but was unconscious (GCS: 5). The skin in the area of the maxillary sinuses was ulcerated, discolored, and scarred, with more involvement of the right sinus and malar area (Figure 1).

On admission, He suffered from loss of vision in his right eye and bilateral redness of the eyes. His respiratory rate was 20 breaths/minute, his blood pressure was 107/49 mmHg, and his pulse rate was 130 bpm. Taking his family history revealed that the patient's aunt and grandmother had a history of DM. His treatment regimen for DM was injection of 6 cc/h regular insulin daily. The patient's laboratory tests were as follows:

PTT=36.3, PT=12.9, Hb=9.5, INR=1.1, WBC=9.3, last patient BS=240, BUN=57, Creatinine=1.4, Na=154, K=7.4 and CRP=61.

Spiral computed tomography scan and magnetic resonance imaging of paranasal sinuses and maxillofacial region were obtained.

Axial spiral computed tomography with reconstructed coronal and sagittal sections



**Figure 1.** A necrotic ulcer surrounded by edema in the right side of the nose and a developing ulcer with bleeding and edema in the left side

revealed increased mucosal thickening and fluid level in the sphenoid sinus. Also, the rest of his paranasal sinuses were opacified. Expansile filling defect in both ethmoidal and maxillary sinuses was seen. Slight remodeling in the bony wall of the paranasal sinuses especially in the maxillary sinuses, related to chronic pansinusitis, was detected. Mild soft tissue edema in the maxillofacial region was also noted. Moreover, bilateral nasal cavities were opacified. Extension of abnormal soft tissue density to the posterior ethmoidal air cells was detected. Subtle thinning of the medial wall of both maxillary sinuses was noted as well (Figure 2A).

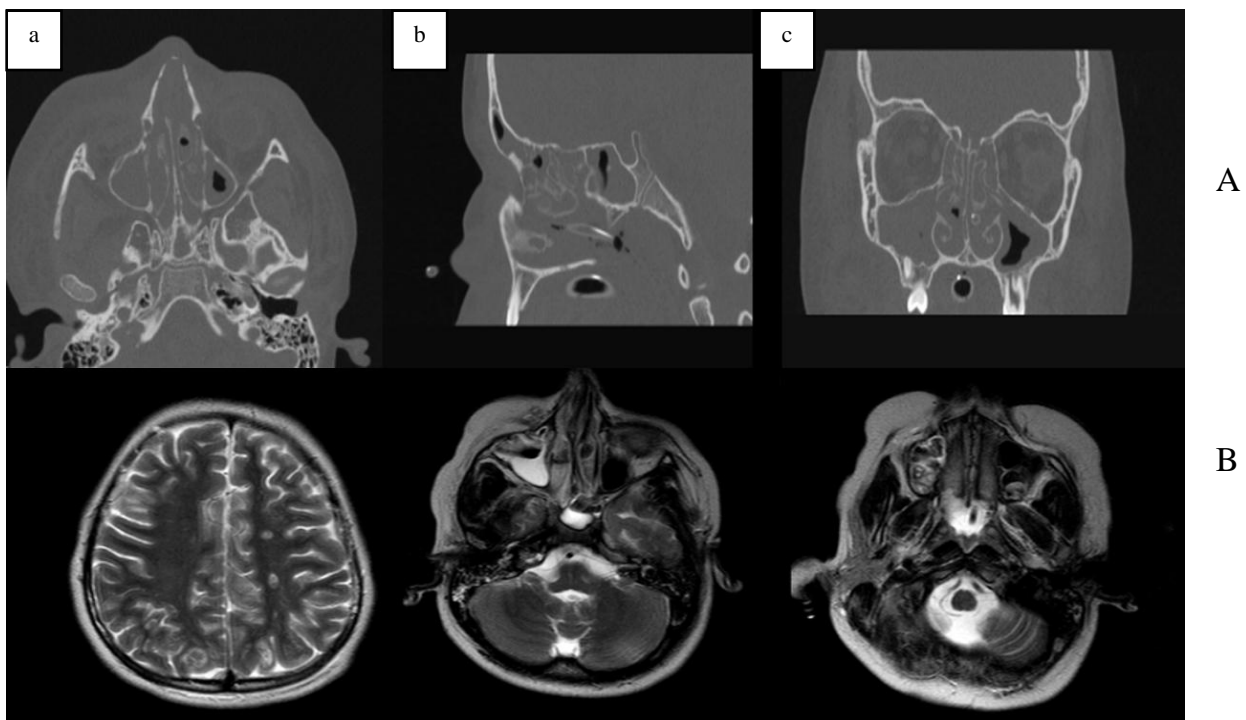
On the T2-weighted sequences of MR images, there was extensive signal abnormality in the subcortical aspect of bilateral parieto-occipital lobe, and periventricular white matter, which was associated with signal void abnormality. It was compatible with micro-bleeding images. In the correlated Gradient echo(GRE) images, several signal void abnormalities distributed in the subcortical bilateral parieto-occipital lobe, and periventricular white matter, confirmed

magnetic resonance imaging findings of the brain, and demonstrated micro-bleeding, edema and also gliosis. In the precontract T1-weighted sequences, there were opacified paranasal sinuses with fluid level of sphenoid sinus as well as ethmoidal and maxillary sinuses. Also, mastoid air cells were opacified. A considerable finding on both T1- weighted and T2- weighted sequences was heterogenous signal pattern in the base of both maxillary sinuses, related to desiccated pus and long-lasting untreated and neglected sinusitis (Figure 2B).

In the first step, after informing his parents and obtaining written informed consent, the patient underwent debridement and biopsy. The initial histopathological examination confirmed the diagnosis of rhino-cerebral mucormycosis. The ultimate treatment for the

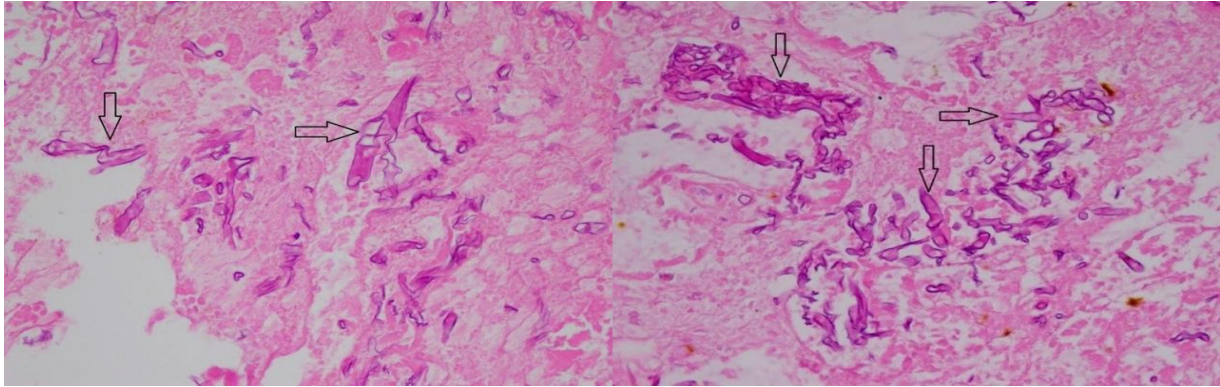
patient was total maxillectomy and tracheostomy. Under general anesthesia, access to the right inferior orbital rim was obtained and both left and right maxillary sinuses were debrided to eliminate necrotic tissues, and left and right maxillary osteotomy were performed. Buccal left and right maxillary sinuses as well as ethmoid and maxillary air cells were sent for pathological investigation. The total maxillectomy specimen showed multiple foci of necrosis and in histopathologic examination, there was extensive necrosis with severe acute inflammation and several infiltrative non-septate and broad hyphae in a necrotic tissue. The diagnosis of mucormycosis was confirmed by pathological assessment (Figure 3).

The external maxillary contour of the nose was reconstructed with titanium mesh and



**Figure 2-A.** a) Axial spiral computed tomography of paranasal sinuses with reconstructed. b) sagittal and c) coronal images indicate opacified paranasal sinuses supplemented by bony remodeling related to long-lasting chronic sinusitis with opacified nasal cavity.

**-B.** Axial T2-weighted sequences from the brain and paranasal sinuses present fluid level in the paranasal sinuses and also filling defect in both maxillary sinuses related to mucosal thickening and hemorrhagic component



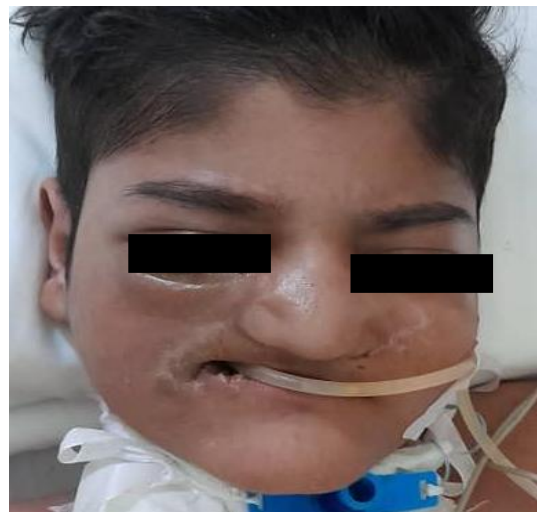**Figure 3.** Microscopic section from sino-nasal and maxillary tissue shows a necrotic background with broad and non-septate invasive mucormycosis hyphae (arrows) (H&E, x400)

fixed with screws. The cutaneous muscle flap was returned and sutured, and then a sterile dressing was applied. The patient received intravenous liposomal amphotericin B, vancomycin and linezolid. After treatment, the patient was hospitalized for nearly 16 months for postoperative follow-up and controlling his diabetes mellitus. Due to his brain condition, the patient was unable to walk at first. He underwent physiotherapy and was able to move his head and shake his hands. Fortunately, after the treatment, the patient's vision completely returned. He was monitored by an ophthalmologist and had no vision problem (Figure 4).

### Discussion

In the head and neck area, Mucorales cause extensive damage by invading the blood vessels, and creating embolism and necrosis, which, if not diagnosed promptly, can lead to disease progression and invasion to vital structures and result in ultimate death of the patient [5]. *Rhizopus arizus* is the most common type of Mucorales that causes mucormycosis. This microorganism normally grows on the soil and various decaying organic materials, and releases many spores into the air that are inhaled by humans. In healthy people, the microorganism is cleared by phagocytes, and is not pathogenic [6].

Numerous risk factors have been reported



**Figure 4.** Patient was monitored by an ophthalmologist after the procedure. His vision completely returned and he no longer had any vision problem

for susceptibility to mucormycosis; among which, DM is the most common [2-4]. Patients with poorly controlled DM or type I DM (insulin-dependent type) that experience periods of ketoacidosis are more likely to develop the disease. Ketoacidosis increases the serum iron level by inhibiting the binding of iron to transferrin. Iron promotes the growth of the fungi. On the other hand, patients with DM suffer from functional defects of phagocytes; thus, they are more prone to mucormycosis than healthy people. Therefore, it seems that blood sugar control is an important factor in controlling the disease and also preventing the occurrence of



mucormycosis [7-9].

The disease affects several different organs, among which, the oral cavity, sinuses, and orbits are the most commonly affected areas in rhiniorbital form. The situation would be more life-threatening in diabetic patients [4]. Since the rhinocerebral type is sometimes not diagnosed early in diabetic patients (due to the presence of nonspecific symptoms), and the disease progresses widely, the algorithm mentioned in the "International Guideline for Clinical Mycology in Europe" should be considered for correct diagnosis and appropriate treatment planning [9,10]. This algorithm contains diagnostic and therapeutic steps for patients with mucormycosis. For an initial diagnosis, complications such as sinusitis, orbital apex syndrome, and development of a single oral ulcer in the palatal area developed in a diabetic patient may be considered as symptoms of the disease. According to the guideline, these symptoms are classified as warning signs. Therefore, dentists can play an important role in preventing the progression of disease by quickly diagnosing and referring such patients after examining and discovering such lesions in the head and neck area. The next step is to request additional imaging of the head and neck region to examine the affected areas and confirm the initial diagnosis, and also for use as a guide for definitive treatment. After clinical examination and imaging, to confirm the initial diagnosis, a smear cytology, culture, and biopsy of the affected site would be the next steps. On histopathological examination, fungal hyphae are typically seen in a broad non-septate form with a right-angle branch [7-9]. The treatment protocol for mucormycosis includes a combination of medication and surgery based on the area involved and the severity of the involvement. In the present case, after the initial steps to diagnose mucormycosis, due to the large area of involvement, the ultimate treatment for the patient was total

maxillectomy and tracheostomy, and both left and right maxillary sinuses were totally debrided. For antifungal treatment, amphotericin B is the first line treatment for mucormycosis, but due to its nephrotoxicity, it is recommended to evaluate the patient's renal function (especially in type I DM) before its administration [9,10].

## Conclusion

Patients with mucormycosis experience several complications after treatment following deformity due to fungal infection or surgery; therefore, correct diagnosis based on clinical and histopathological findings and timely referral of patients can greatly affect the prognosis of the disease and the treatment process.

## References

1. Martínez-Herrera E, Frías-De-León MG, Julián-Castrejón A, Cruz-Benítez L, Xicohtencatl-Cortes J, Hernández-Castro R. Rhino-orbital mucormycosis due to *Apophysomyces ossiformis* in a patient with diabetes mellitus: a case report. *BMC Infect Dis*. 2020 Aug 18;20(1):614.
2. Skiada A, Pavleas I, Drogari-Apiranthitou M. Epidemiology and Diagnosis of Mucormycosis: An Update. *J Fungi (Basel)*. 2020 Nov 2;6(4):265..
3. R R, M R M, Kumar SP. Mucormycosis Following Tooth Extraction in a Diabetic Patient: A Case Report. *Cureus*. 2020 Aug 15;12(8):e9757.
4. Jeong W, Keighley C, Wolfe R, Lee WL, Slavin MA, Kong DCM, et al. The epidemiology and clinical manifestations of mucormycosis: a systematic review and meta-analysis of case reports. *Clin Microbiol Infect*. 2019 Jan;25(1):26-34.
5. Pramanik P, Pramanik P. Coincidence of uncontrolled diabetes mellitus and COVID-19 Is a serious threat to Mucormycosis: a systematic review. *World Wide J Multidiscip Res Dev*. 2021;7(7):6-13.
6. Reid G, Lynch JP 3rd, Fishbein MC, Clark NM. Mucormycosis. *Semin Respir Crit Care Med*. 2020 Feb; 41(1):99-114.
7. Chen YX, He YX, Zhou H, Wang M, Su SO. Rapidly progressive rhino-orbito-cerebral mucormycosis in a patient with type 2 diabetes: A case report. *Exp Ther Med*. 2017

- Mar;13(3):1054-6.
8. Wang R, Sheng M, Shi F, Zhao Y, Zhao L, Wu J, et al. Dysfunctional phagocytosis capacity, granulocyte recruitment and inflammatory factor secretion of Kupffer cells in diabetes mellitus reversed by Lidocaine. *Diabetes Metab Syndr Obes.* 2018 Nov 26;11:827-34.
9. Wang J, Li Y, Luo S, Zheng H. Rhinocerebral mucormycosis secondary to severe acute pancreatitis and diabetic ketoacidosis: a case report. *Diagn Pathol.* 2021 Apr 21; 16(1):34.
10. Corzo-León DE, Chora-Hernández LD, Rodríguez-Zulueta AP, Walsh TJ. Diabetes mellitus as the major risk factor for mucormycosis in Mexico: Epidemiology, diagnosis, and outcomes of reported cases. *Med Mycol.* 2018 Jan 1;56(1): 29-43.