



## Comparison of the Diagnostic Accuracy of Digital Intraoral Radiography with PSP and CBCT in the Detection of Horizontal and Vertical Dental Root Fractures

Talayi Pour AR<sup>1</sup>, Hafezi L<sup>2</sup>, Yarahmadi A<sup>3\*</sup>, Ghaznavi A<sup>4</sup>, Iranparvar A<sup>5</sup>, Sahabi L<sup>5</sup>

<sup>1</sup>Professor; Oral and Maxillofacial Radiology Dept, and Member of Cranio Maxillofacial Research Center, Dental Branch of Tehran, Islamic Azad University, Tehran, Iran.

<sup>2</sup>Assistant Professor; Oral and Maxillofacial Radiology Dept, Dental Branch of Tehran, Islamic Azad University, Tehran, Iran.

<sup>3</sup>Post Graduate Student, Radiology Dept, Dental Branch, Islamic Azad University, Tehran, Iran.

<sup>4</sup>Assistant Professor; Oral and Maxillofacial Radiology Dept Oromeyeh Dental Faculty Oromeyeh University, Oromeyeh, Iran.

<sup>5</sup>Dentist

### ARTICLE INFO

*Article Type*  
Original Article

#### Article History

Received: April 2016

Accepted: July 2016

ePublished: Oct 2016

#### Keywords:

**Dental Digital Radiography,**  
**Photostimulable Phosphor**  
**Plate,**  
**Cone Beam Computed**  
**Tomography,**  
**Horizontal root fracture,**  
**Vertical root fracture**

### ABSTRACT

**Background and Aim:** Clinical and radiographic diagnoses of dental root fractures have always been difficult and require high accuracy in dental care and treatment. The aim of this study was to compare the diagnostic accuracy of intraoral digital radiography (PSP) and CBCT in the detection of horizontal root fracture (HRF) and vertical root fracture (VRF).

**Materials and Methods:** For this experimental study, 60 human mandibular teeth (24 anterior and 36 posterior multi-rooted teeth) were selected. Fifteen randomly-selected teeth were fractured horizontally while the next 15 randomly-selected teeth were fractured vertically by use of a hammer and then the pieces were glued back together and were placed in sheep mandibles. Radiographic images of all the teeth were taken using intraoral digital radiography (PSP) and CBCT methods. Afterwards, two oral and maxillofacial radiologists assessed the images separately. The data were subjected to diagnostic analytic tests.

**Results:** There were significant differences in specificity, sensitivity, positive predictive value and negative predictive value between digital intraoral radiography (PSP) and CBCT in the detection of HRF and VRF. Kappa value for inter-observer and intra-observer agreement in VRF equaled 73.3% for CBCT and 54.2% for PSP, while in HRF it equaled 63.3% for CBCT and 55.4% for PSP.

**Conclusion:** CBCT method has higher specificity and sensitivity in the detection of HRF and VRF compared with intraoral digital radiography.

Please cite this paper as: Talaeypour A R, Hafezi L, Yarahmadi A, Ghaznavi A, Iranparvar A, Sahabi L. Comparison of the Diagnostic Accuracy of Digital Intraoral Radiography with PSP and CBCT in Detection of Horizontal and Vertical Dental Root Fractures. J Res Dentomaxillofac Sci. 2016;1(4):32-38.

\*Corresponding author:

Yarahmadi A

Email: [dr.yarahmadi@yahoo.com](mailto:dr.yarahmadi@yahoo.com)

## Introduction:

Root fracture is among the most common causes of endodontic treatment failures. <sup>(1,2)</sup> Clinical and radiographic diagnoses of dental root fractures have always been difficult. Radiographic diagnosis of dental root fracture requires high accuracy in dental care and treatments. Root fractures can also be assessed by routine dental examinations. <sup>(2,3)</sup> Overall, dental root fractures comprise 0.5 to 7% of the injuries that inflict the permanent dentition. <sup>(2)</sup> Horizontal and vertical root fractures (HRF and VRF) are difficult to detect due to the challenges in diagnosis and tracing on intraoral radiographs, except when definite clinical findings exist. This difficulty in diagnosis leads to unnecessary tooth extractions, poor long-term prognosis and extensive bone loss. <sup>(2, 3, 4)</sup> Conventional and digital intraoral radiography are the most common techniques for tracing dental root fractures.

Dental root fractures have become detectable since two-dimensional radiography was implemented in dentistry in 1896. <sup>(5, 6)</sup> Nowadays, intraoral radiography with Photostimulable Phosphor Plate (PSP) is being used for detection of root fracture as a digital intraoral radiography method. <sup>(7)</sup> Conventional two-dimensional radiography can be completed with a third view (the orofacial view). Cone Beam Computed Tomography (CBCT) was introduced in dento-alveolar imaging in 1998. <sup>(8)</sup> CBCT has been implemented as a valuable imaging modality in different dentistry fields such as surgery and orthodontics. Nevertheless, the advantages and limitations of CBCT in dental traumatology, especially in the diagnosis of teeth with fractured roots have remained indefinite. <sup>(9)</sup>

The present study aimed to compare the diagnostic accuracy of digital intraoral radiography (two-dimensional) and CBCT (three-dimensional) in the detection of the presence or absence of HRF and VRF at the radiology department of the dental school of Islamic Azad University of Tehran during 2013-2014.

## Materials and methods:

In this in vitro diagnostic study, 60 anterior

and multi-rooted posterior teeth (24 anterior and 36 posterior teeth) without fractures, cracks or root fillings were selected and coded. Dental sockets were formed with a bur in sheep mandibles to hold and stabilize the teeth. Fifteen randomly-selected teeth were fractured horizontally, while the next 15 randomly-selected teeth were fractured vertically by a hammer, and then the pieces were glued back together and the teeth were placed inside the dental sockets. In each mandible, half the teeth were fractured either horizontally or vertically. Since the teeth were fractured by use of a hammer, the roots in multiple-rooted teeth were randomly fractured.

Afterwards, each mandible was radiographed with PSP (using parallel method with the aid of a film holder and using DIGORA OPTIME device (Soredex, Helsinki, Finland) with radiographic exposure parameters of  $t=0.1$  s,  $kVp=70$ ,  $mA=8$  and resolution=  $3/14$  lp/mm) and the digital images were saved. Afterwards, CBCT images were obtained from each mandible in axial and coronal views using NEWTOM VGi CBCT (QR SRL Company, Verona, Italy) with an  $8*8$  cm field of view (Fov) in high resolution mode and the images were saved. (Fig 1,2)

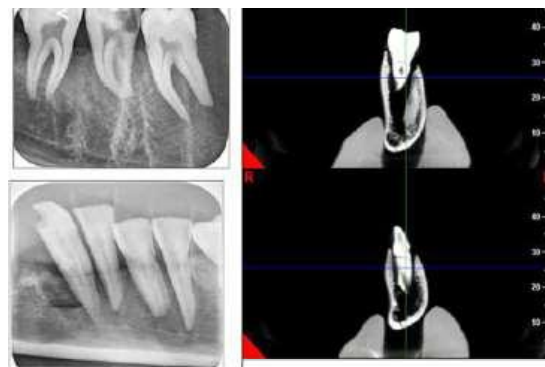
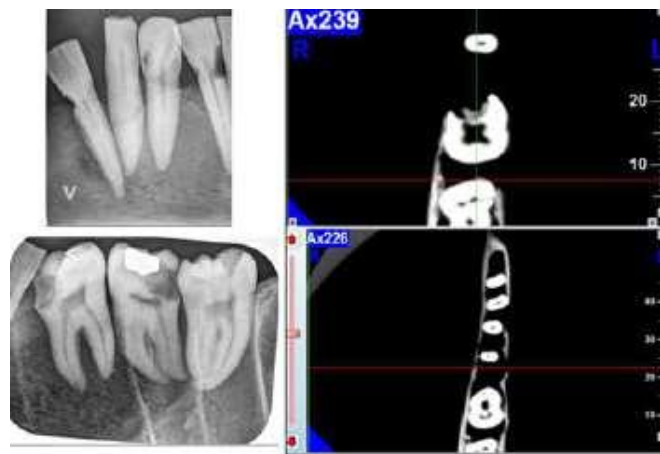


Fig 1-Digital image and CBCT image coronal view



**Fig 2- Digital image and CBCTimag Axial view**

The images were evaluated separately by two oral and maxillofacial radiologists. The observers independently evaluated the images of each fracture type obtained by each method twice in a time interval separated by three weeks (intra-observer and inter-observer reliability).

The results were compared regarding the reliability and were registered in designated lists. The data were statistically analyzed by use of statistical indices (specificity, sensitivity, positive predictive value, negative predictive value, and kappa coefficient) using SPSS software version 22 (SPSS Inc., Chicago IL, USA).

**Result:**

After analyzing 120 radiographic images obtained by digital intraoral radiography (PSP) and CBCT, the following results were achieved:

The results are presented in tables 1 to 4. According to tables 1 and 2, CBCT has the highest sensitivity and specificity in the diagnosis of HRF and VRF.

**Table 1- Diagnostic results of HRF evaluation based on the assessed radiographic modality**

System	Observer	Evaluation	Specificity	Sensitivity	PPV	NPV	Kappa Value
CBCT	First	First	93,3%	73,3%	90,9%	73,7%	60%
		Second	93,3%	86,7%	90,9%	73,7%	60%
		Mean	93,3%	80%	90,9%	73,7%	60%
PSP	First	First	73,3%	66,7%	73,3%	70%	54,7%
		Second	80%	66,7%	81,2%	68%	56,7%
		Mean	76%	66,7%	77,25%	69%	55,7%
CBCT	Second	First	86,7%	77,3%	84,6%	76,5%	60%
		Second	92,3%	80%	92,3%	82,4%	73,3%
		Mean	89,5%	78,8%	88,4%	79,4%	66,6%
PSP	Second	First	66,7%	71,3%	68,8%	69%	57%
		Second	73,3%	68%	75%	71,6%	53,3%
		Mean	70%	69,6%	71,9%	70%	55,1%

Sensitivity: the ability of a system to diagnose fractured samples

Specificity: the ability of a system to diagnose intact samples

PPV: the percentage of correct diagnoses of fractured samples by the observer

NPV: the percentage of correct diagnoses of intact samples by the observer

**Table 2- Diagnostic results of VRF evaluation based on the assessed radiographic modality**

System	Observer	Evaluation	Specificity	Sensitivity	PPV	NPV	Kappa Value
CBCT	First	First	100%	73.3%	100%	78.9%	73.3%
		Second	93.3%	73.3%	91.1%	78.8%	66.7%
		Mean	96.6%	73.3%	95.5%	78.8%	70%
PSP	First	First	73.7%	46.7%	63.6%	57.9%	52%
		Second	86.7%	60%	81.8%	68.4%	56,2%
		Mean	80.2%	53.3%	72.7%	63.1%	54,1%
CBCT	Second	First	93.2%	80%	92.3%	82.4%	73.3%
		Second	93.3%	86.7%	92.9%	87.5%	80%
		Mean	93.2%	83.3%	92.5%	84.9%	76.6%
PSP	Second	First	73.3%	53.3%	66.7%	61.1%	53.7%
		Second	86.7%	73.3%	84.6%	76.5%	55%
		Mean	80%	63.3%	75.6%	68.8%	54.3%

Sensitivity: the ability of a system to diagnose fractured samples

Specificity: the ability of a system to diagnose intact samples

PPV: the percentage of correct diagnoses of fractured samples by the observer

NPV: the percentage of correct diagnoses of intact samples by the observer

CBCT has higher sensitivity (79.4%) for detection of HRF compared with digital intraoral radiography with PSP (68.1%). Also, CBCT has higher specificity (91.4%) in the detection of intact samples compared with digital intraoral radiography with PSP (73%). (Table 3) CBCT has higher sensitivity (78.3%) in the detection of VRF compared with digital intraoral radiography with PSP (58.3%). CBCT has higher specificity (94.9%) in the detection of intact samples compared with digital intraoral radiography with PSP (80.1%). (Table 3)

**Table 3- Diagnostic results of the two observers regarding HRF and VRF based on the evaluated radiographic modality**

Fracture type	System	Specificity	Sensitivity	PPV	NPV	Kappa Value
HRF	CBCT	91.4%	79.4%	89.6%	76.5%	63.3%
	PSP	73%	68.1%	74.5%	69.5%	55.4%
VRF	CBCT	94.9%	78.3%	94%	81.8%	73.3%
	PSP	80.1%	58.3%	74.1%	65.9%	54.2%

Positive predictive value (PPV) is significantly higher in CBCT compared with digital intraoral radiography with PSP in the detection of HRF. This means that the observers had 89.6% correct diagnoses of HRF with CBCT system. While PPV equaled 74.5% in PSP system, which means that the observers had 74.5% cases of correct diagnoses of HRF with PSP system. Negative predictive value (NPV) (correct diagnosis of intact samples) equaled 76.5% in CBCT and 69.5% in intraoral radiography with PSP. (Table 3)

Likewise, PPV is significantly higher in CBCT compared with digital intraoral radiography with PSP in the detection of VRF, while PPV equaled 74.1% in PSP system. NPV equaled 81.8% in CBCT and 65.9% in digital

Intra-observer and inter-observer agreement between the two observers in the detection of HRF were higher in CBCT compared with digital radiography with PSP. Kappa value for inter-observer and intra-observer agreement equaled 63.3% for CBCT and equaled 55.4% for PSP. (Table 4) Likewise, Intra-observer and inter-observer agreement between the two observers in the detection of VRF were higher in CBCT compared with digital intraoral radiography with PSP. Kappa value for inter-observer and intra-observer agreement equaled 73.3% for CBCT and equaled 54.2% for PSP. (Table 4)

**Table 4- Inter-observer and intra-observer agreement regarding HRF and VRF based on the evaluated radiographic modality**

Agreement	Observer	System	Kappa Value
Intra-observer (HRF)	1	CBCT	60%
		PSP	55.7%
	2	CBCT	66.6%
		PSP	55.1%
Inter-observer (HRF)	CBCT		63.3%
	PSP		55.4%
Intra-observer (VRF)	1	CBCT	70%
		PSP	54.1%
	2	CBCT	76.6%
		PSP	54.3%
Inter-observer (VRF)	CBCT		73.3%
	PSP		54.2%

## Discussion:

HRF and VRF have always been difficult to



diagnose and trace on intraoral radiographs. This difficulty in diagnosis leads to unnecessary tooth extractions, poor long-term prognosis and extensive bone loss.<sup>(2-4)</sup>

In this *in vitro* study, the diagnostic accuracy of digital intraoral radiography with PSP and CBCT in the detection of HRF and VRF was assessed.

60 human mandibular anterior and multi-rooted posterior teeth were selected for this study. Sheep mandibles were used for stabilizing the teeth. Dental roots were fractured randomly by use of a hammer, (similar to the method used by Avsever et al and da Silveira et al)<sup>(10, 11)</sup> and then the fractured pieces were glued back together and were placed inside the dental sockets. Afterwards, each mandible was radiographed with PSP and CBCT similar to the method used by Kambungton et al.<sup>(12)</sup>

The results showed that CBCT has higher diagnostic accuracy than digital intraoral radiography with PSP in the detection of HRF and VRF. Moreover, inter-observer and intra-observer agreements between the observers were higher in CBCT system compared to digital intraoral radiography with PSP.

Considering the results, the accuracy of CBCT was higher in the detection of intact and fractured samples, which can be attributed to three-dimensional evaluation of the presence or absence of fracture line in different sections of the teeth. Also, many radiographic errors of two-dimensional radiography techniques (like digital intraoral radiography) such as overlapping of adjacent teeth and superimposition of different structures are absent in CBCT method due to the ability to visualize each tooth at different angles and views.

Bornstein et al reported that detection of the location and angle of the root fracture is significantly different in CBCT method compared with the diagnoses based merely on intraoral radiography.<sup>(9)</sup> This finding is in line with the results of the present study.

Kambungton et al showed that no statistically significant differences exist among CBCT, digital and conventional intraoral radiography in the detection of VRF in single-rooted mandibular teeth.<sup>(12)</sup> This difference with our results can be attributed to the use of various types of teeth (anterior and multi-rooted posterior teeth) in the present study.

Wang et al concluded that CBCT is significantly more accurate and valid in the diagnosis of root fractures in comparison with intraoral radiography,<sup>(13)</sup> which is in line with the results of the present research.

Avsever et al showed that the diagnostic accuracy of CBCT is significantly higher for tracing HRF compared with digital intraoral radiography with CCD and stated that CBCT should be selected as the most reliable imaging modality in diagnosis of HRF.<sup>(10)</sup> This finding is in accordance with the results of our study.

A report by Brady et al showed that periapical radiography and CBCT were unreliable in the detection of partial fractures and that the width of the fracture can influence the accuracy of CBCT. Also, they found that complete fractures can be traced more easily than partial fractures by all radiographic modalities.<sup>(14)</sup> In the present study, which only involved complete fracture lines, specificity and PPV of CBCT were extremely high and reliable in tracing the mentioned fractures.

Edlund et al reported PPV of 92%, sensitivity of 88% and specificity of 95% for CBCT and stated that CBCT has high accuracy in the detection of VRF,<sup>(15)</sup> which confirms the results of the present study.

After evaluating conventional intraoral radiographs and CBCT images, da Silveira et al stated that the results of the diagnostic tests have shown similar capability of the detection of VRF for periapical radiography and CBCT scans in non-endodontically treated teeth and after metallic post insertion, and they also stated that radiographic evaluation at multiple horizontal angles should be considered as the first complementary modality in the detection of VRF. They concluded that when conventional radiography is incapable of rendering adequate information, CBCT can be used.<sup>(11)</sup> This finding contradicts our results. The difference can be attributed to the use of single-rooted teeth and multiple exposures at different horizontal angles in the mentioned study.

Bechara et al compared CBCT and PSP systems and reported that images with small FOV showed a significant higher accuracy and specificity in the detection of dental root fractures compared with the images with large FOV and enhanced PSP images. The specificity of enhanced PSP im-

ages was slightly higher than that of the images with small FOV, while it was significantly higher than the specificity of the images with large FOV. Therefore, they concluded that images with small FOV are suitable for the detection of fractures in endodontically treated teeth. Images taken with PSP sensors rendered the lowest number of false positive results and this method can be considered safe.<sup>(16)</sup>

Considering the expenses and facilities, when definite clinical signs of root fracture are present, digital intraoral radiography can be used as the first step but if CBCT is available, it is strongly recommended to use this imaging modality as the first evaluative step.

### Conclusion:

CBCT has higher sensitivity and specificity in the detection of horizontal and vertical root fractures compared with digital intraoral radiography.

### Acknowledgements:

The authors sincerely thank Dr. Shadi Saghaei for histopathology investigations.

### Conflicts of Interest:

The authors of this manuscript certify that they have no conflicts of interest regarding this research.

### References:

1. Martins JNR, Canta JP, Coelho A, Baharestani M. Vertical root fracture diagnosis of crowned premolars with root canal treatment – Two case reports. *Rev Port Estomatol Med Dent Cir Maxilofac* 2014;55(1):60–64.
2. Edlund M, Nair MK, Nair UP. Detection of vertical root fractures by using cone- beam computed tomography: A clinical study. *J Endod* 2011;37(6):768-72.
3. Farman AG, Farman TT. A comparison of 18 different x-ray detectors currently used in dentistry. *Oral Surg Oral Med Oral Pathol Oral Radiol Endod* 2005;99(4):485-9.
4. Dehghani M, Montazer lotf elahi H, Moeini M, Bardal R. Comparing the accuracy of cone beam computed tomography, digital intraoral radiography and conventional intraoral radiography in the measurement of periodontal bone defects. *J Res Dentomaxillofac Sci* 2016;1(1):34-39.
5. De Vos W, Casselman J, Swennen GR. Cone beam

computerized tomography (CBCT) imaging of the oral and maxillofacial region: A systematic review of the literature. *Int J Oral Maxillofac Surg* 2009;38(6):609-25.

6. Lofthag-Hansen S. Cone beam computed tomography radiation dose and image quality assessments. *Swed Dent J Suppl* 2010;(209):4-55.

7. Mehralizade S, Nemati Anaraki S, Sakhdari S, Miraba S, Amiri Siavashani M Bayat S. Comparing the diagnostic accuracy of two different resolution radiographs captured with PSP digital intraoral receptors in detection of secondary caries (In Vitro). *J Res Dentomaxillofac Sci* 2016;1(1):40-4

8. Alamri HM, Sadrameli M, Alshalhoob MA, Sadrameli M, Alshehri MA. Applications of CBCT in dental practice: A review of the literature. *Gen Dent* 2012;60(5):390-400.

9. Bornstein MM, Wölner-Hanssen AB, Sendi P, von Arx T. Comparison of intra oral radiography and limited cone beam computed tomography for the assessment of root-fractured permanent teeth. *Dent Traumatol* 2009;25(6):571-7.

10. Avsever H, Gunduz K, Orhan K, Uzun I, Ozmen B, Egrioglu E, Midilli M. Comparison of Intraoral radiography and cone -beam computed tomography for the detection of horizontal root fractures: an in vitro study. *Clin Oral Investig* 2014;18(1):285-92.

11. da Silveira PF, Vizzotto MB, Liedke GS, da Silveira HL, Montagner F, da Silveira HE. Detection of vertical root fractures by conventional radiographic examination and cone beam computed tomography- an in vitro analysis. *Dent Traumatol* 2013;29(1):41-6.

12. Kambungton J, Janhom A, Prapayasatok S, Pongsiriwet S. Assessment of vertical root fractures using three imaging modalities: cone beam CT, intraoral digital radiography and film. *Dentomaxillofac Radiol* 2012;41(2):91-5.

13. Wang P, Yan XB, Lui DG, Zhang WL, Zhang Y, Ma XC. Detection of dental root fractures by using cone-beam computed tomography. *Dentomaxillofac Radiol* 2011;40(5):290-8.

14. Brady E, Mannocci F, Brown J, Wilson R, Patel S. A comparison of cone beam computed tomography and periapical radiography for the detection of vertical root fractures in nonendodontically treated teeth. *Int Endod J* 2014;47(8):735-46.

15. Edlund M, Nair MK, Nair UP. Detection of vertical root fractures by using cone-beam computed tomography: a clinical study. *J Endod* 2011;37(6):768-72.

16. Bechara B, McMahan CA, Noujeim M, Faddoul T, Moore WS, Teixeira FB, et al. Comparison of cone beam CT scans with enhanced photostimulated phosphor plate images in the detection of root fracture of endodontically treated teeth. *Dentomaxillofac Radiol* 2013;42(7):20120404.